

OVERVIEW

- **Severe outbreak of salmonellosis in a dairy herd**
- **Fatal coccidiosis in a weaned goat kid**
- **High ewe losses due to louping ill**

GENERAL INTRODUCTION

November proved to be a dry month across Scotland as a whole. The mean temperature was 0.8°C below the thirty-year average (1991-2020) and total rainfall and sunshine hours were 74 and 107 percent of average respectively.

DISEASE ALERTS

The following conditions were reported by SRUC VS disease surveillance centres in February 2023. Given similar climatic and production conditions, they could also be important this year.

- **Cerebrocortical necrosis in weaned beef calves** Cerebrocortical necrosis (CCN) is associated with thiamine deficiency or excessive sulphur intake. In cattle it is most commonly seen in animals between the ages of six and 18 months. Cases are often sporadic, but outbreaks can occur. Onset of disease may follow a change to the ration and an association with high-carbohydrate low-forage diets has been made. This may increase the risk by triggering multiplication of thiaminase producing bacteria in the rumen. There are no diagnostic tests for CCN in live animals and brain histopathology or response to treatment is required to confirm the diagnosis.
- **Pregnancy toxæmia in ewes** Risk factors can include inappropriate body condition, inadequate/reduced concentrate intakes due to insufficient trough space, bullying, lameness, or excessive single feeds of concentrates leading to subclinical rumen acidosis and consequent reduced feed intake. Dietary energy supply can be monitored via forage analysis and ration formulation plus checking BOHB levels around three weeks prior to lambing. Five twin and five triplet bearing ewes due to lamb in the first cycle should be sampled.

CATTLE

Parasitic diseases

Six individual faecal samples were submitted from a group of healthy spring-born weaned beef calves. Growth rates were as expected, and egg count monitoring was initiated as part of the Preparing for Sustainable Farming Animal Health and Welfare Interventions. The samples were pooled for examination and a *Strongyle* egg count of 625 eggs per gram (epg) was detected. Pour-on ivermectin was administered according to the data sheet instructions and six individual post dosing faecal samples were collected two weeks later. A pooled egg count found 300 *Strongyle* epg prompting individual testing with results of <50, <50, <50, 200, 250 and 750 epg. Further testing at the University of Glasgow using an in-house multiplex PCR identified a predominance of the less pathogenic *Cooperia oncophora* (66 to 85.1 percent). *Ostertagia ostertagi* eggs were also present post treatment (14.9 to 34 per cent). The results confirmed treatment inefficacy and are suspicious of anthelmintic resistance particularly in *Cooperia oncophora*. Confidence would be increased if the same calves had been sampled on both occasions, and if PCR speciation results were available for the pre-treatment samples. It would also be of interest to repeat the testing on untreated calves using injectable ivermectin rather than a pour on formulation. Although the sampled animals were not suffering from clinical parasitic gastroenteritis, the case highlights the need for responsible anthelmintic use and monitoring in cattle. The Veterinary Medicines Directorate were informed. There are few published cases of anthelmintic resistance in cattle nematodes in the UK but it appears to be more widely recognized in Ireland.^{1,2,3}

Generalised and systemic conditions

A 500 to 600 cow dairy herd experienced a severe outbreak of salmonellosis due to *Salmonella enterica* serotype Dublin with the death of more than ten cows over the course of a week. Affected animals appeared weak and died within 72 hours with no signs of diarrhoea or dehydration. There was herd wide milk drop with the yield of sick cows falling from 40 litres to zero within 24 hours. The case fatality rate was reported to be around 60 per cent and a small number of abortions also occurred. Two cows were examined postmortem and findings were consistent with septicaemia. Possible predisposing factors included an increased stocking density with one third of the shed out of use while new cubicle mattresses were fitted. A group of thirty in-calf homebred heifers had been added to the shed two weeks before and none were reported to be ill. Many of the acutely sick cows were reported to have had swollen

hocks prior to becoming ill and *Mycoplasma wenyonii* had recently been detected. It was postulated that co-infection may have increased the severity of the outbreak.

Alimentary tract disorders

A two-year-old Aberdeen Angus bull was purchased and transported 20 miles from farm to farm. It appeared well until three days later when it was found recumbent and in pain. Various treatments were administered but it died the following day. Postmortem examination revealed a right displaced and dilated abomasum with consequent rupture and peritonitis. Localised areas of ulceration were noted adjacent to the pylorus. Prior to the move the bull had been housed in a straw bedded pen on a diet of straw and concentrate feed. After purchase it was housed on slats with heifers and fed a grass silage based TMR plus a small quantity of concentrates. The stress associated with transportation and management changes were considered to be predisposing factors in this case.

Respiratory tract diseases

A four-month-old Belgian blue cross calf was found dead of suspected pneumonia. It had been purchased two months earlier and vaccinated against IBR and *Mannheimia haemolytica*. Postmortem examination identified anteroventral sub-pleural emphysema (Fig 1) suggestive of infection with bovine respiratory syncytial virus (BRSV). There was additional interlobular emphysema and large emphysematous bullae in the diaphragmatic lobes plus localised areas of consolidation in the anterior lung lobes. RSV, *Mycoplasma bovis* and *Pasteurella multocida* were detected by PCR carried out on lung tissue and histopathology confirmed active lesions consistent with RSV and *M bovis* infection. RSV was a frequent diagnosis in south-west Scotland during November, but this does not appear to have been replicated in other areas.

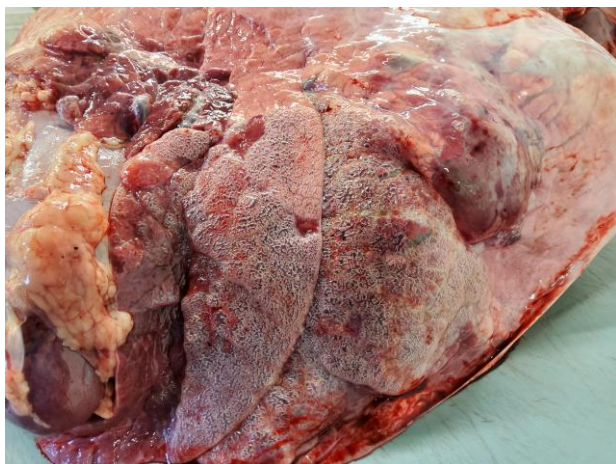

Figure 1 – Typical RSV-associated pathology in a four-month-old weaned calf

Nervous system disorders

A six-month-old Aberdeen Angus calf from a group of 30 cows and calves at grass was found in lateral recumbency. It was described as having “flickering” eyes and was kicking and throwing its head back. It was treated with magnesium and vitamin B1 but died the next day. No other cattle were similarly affected. Postmortem examination was unremarkable but brain histopathology confirmed a diagnosis of listeriosis which is an infrequent diagnosis in this age of calf. Eruption of the first molars between the ages of five and six months could be a possible risk factor by facilitating entry of *Listeria monocytogenes* through the mucosa.

Musculoskeletal disorders

A Limousin cross bull calf was submitted live from a 200-cow beef herd to investigate multiple congenital deformities that had been noted following a caesarean delivery. Examination confirmed deviation of the mandible to the left, a protruding flaccid tongue (Fig 2), cleft palate and arthrogyposis. Cleft palate and arthrogyposis are often seen concurrently, and potential aetiologies can have a genetic, tetratogenic or nutritional basis. No other cases had been noted at the time of submission. No infectious agents were detected, and the cause remained unknown. EDTA blood samples were requested from the dam and sire.

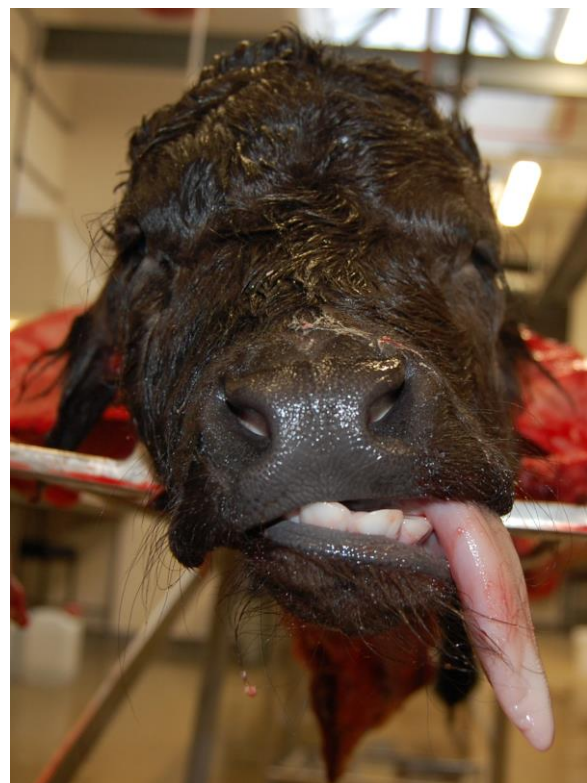


Figure 2 – Congenital mandibular deformity in a Limousin cross calf

SMALL RUMINANTS

Parasitic diseases

A six-month-old alpine x golden Guernsey goat was diarrhoeic for 48 hours prior to death. It was reported to be healthy, however postmortem examination found it to be very thin with no body fat. A mild to moderate volume of ascitic fluid was noted suggesting hypoalbuminaemia. Histopathology indicated that the ill thrift was likely to be a consequence of parasitic enteritis and described lesions consistent with active coccidiosis. Anthelmintic treatment had been administered twice in the previous week, and there was no evidence of a worm burden at the time of death. However, a very high coccidial count of 482,400 oocysts per gram (opg) was considered to be the cause of diarrhoea and death. Further testing confirmed that 90 per cent of the oocysts had originated from species considered to be highly pathogenic including *Eimeria arloingi*, *christensenii*, *ninakohlyakimovae* and *hirsi*.

Generalised and systemic conditions

Six purchased lambs were found dead between 10 and 14 days after moving to their new holding. Doramectin, triclabendazole and the first dose of a clostridial/pasteurella vaccine had been given on arrival. On-farm postmortem examination revealed pinpoint pale liver lesions and inflammation of the caecal mucosa. Differential diagnoses included listeriosis, yersiniosis or systemic pasteurellosis, with the latter also suggested by the history of recent transport. Bacteriology of intestinal content proved negative for *Listeria* and *Yersinia* spp but *Bibersteinia trehalosi* was recovered. Histopathology confirmed ulcerative and haemorrhagic typhlocolitis plus necrosuppurative hepatitis. Colonies of bacteria with a morphology consistent with *B. trehalosi* were associated with both lesions confirming the suspected diagnosis.

Nervous system disorders

A group of 400 easycare ewes were moved onto hill pasture and two weeks later 24 animals developed a range of clinical signs including hind limb ataxia, recumbency, teeth chattering and opisthotonos. One live and one dead ewe were submitted along with blood samples from four other affected ewes. Postmortem examination was unremarkable however all six animals tested positive in the louping ill antibody ELISA with high levels of IgM indicating recent exposure to the virus. Neuropathology findings of a mononuclear meningoencephalitis characterised by perivascular cuffs and neuron necrosis were typical of louping ill. The sheep were removed from the pasture but deaths continued for a further two weeks with a total of 60 ewes lost. Concurrent infection with *Anaplasma phagocytophilum* (tick borne fever) can increase the severity of louping ill outbreaks and the spleens of both ewes tested positive

on PCR. The group had grazed the same pasture in spring without any issues suggesting that either tick activity was low at that time and/or the numbers of infected tick had significantly increased over the summer.

A live three-year-old mule ewe was submitted to investigate hind limb paralysis which had developed four days after the group had been brought off the hill. No problems were noted at the time of gathering. The farmer reported similar cases in 2022 and two others in the past few weeks. The ewe frequently adopted a dog-sitting posture (Fig 3a) and clinical examination confirmed paralysis of both hind limbs with no withdrawal or deep pain reflex. Forelimb reflexes were normal, and it was bright and alert. Postmortem examination revealed an abscess within the intervertebral disc at T12-13 with associated osteomyelitis and swelling of the ventral vertebral ligament. The abscess extended into the spinal canal (Fig 3b) causing compression of the spinal cord at this level. *Fusobacterium necrophorum* was isolated from the abscess and considered to be a consequence of a previous bacteraemia followed by bacterial localisation within the intervertebral disc. The source of the bacteria was not clear. *Anaplasma phagocytophilum* DNA was detected by PCR however further grazing history would be required to determine the potential significance of this.

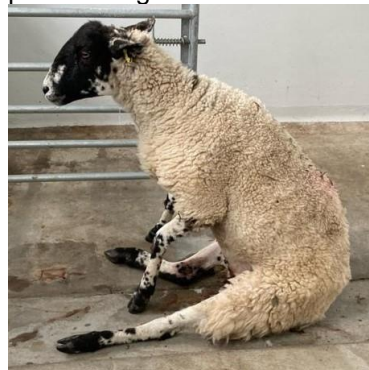


Figure 3a

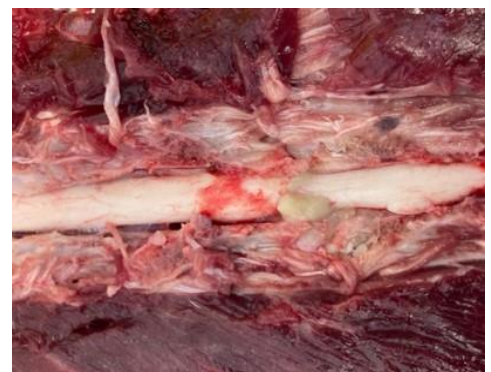

Figure 3b

Figure 3 - Dog sitting posture (a) in a mule ewe with a spinal abscess (b)

Circulatory system disorders

A two-year-old border Leicester ewe from a pedigree hobby flock died unexpectedly three days after it was found cast in the field. Once righted it was noted to be lame and housed for treatment and monitoring. Postmortem examination confirmed septic arthritis of the right stifle from which *Erysipelas rhusiopathiae* was cultured. Lesions of vegetative endocarditis were found on both atrio-ventricular valves and were most severe on the right. A mixed growth of *E. rhusiopathiae* and *Streptococcus infantarius* was isolated from this site. *S. infantarius* was also isolated from the lung and liver indicating a terminal bacteraemia. *E. rhusiopathiae* was considered to be the primary pathogen and *S. infantarius* an opportunistic infection most likely arising from the intestinal tract.

References:

1. Bartley DJ, Jewell NJ, Andrews LM, Mitchell S, Morrison AA. Molecular and phenotypic characterisation of fenbendazole resistance in a field-derived isolate of *Ostertagia ostertagi*. *Vet Para*, 2021;289:109319
2. Kelleher AC, Good B, de Waal T, Keane OM. Anthelmintic resistance among gastrointestinal nematodes of cattle on dairy calf to beef farms in Ireland. *Irish Vet J* 2020; 73(1):1-8
3. Sargison N, Wilson D, Scott P. Relative inefficacy of pour-on macrocyclic lactone anthelmintic treatments against *Cooperia* species in Highland calves. *Vet Rec* 2009; 164(19): 603